

Modified Baron score

A number of scores for evaluation of the severity of disease at endoscopy are available. The Baron score was published in 1964 and was based on a small subset of patients and before flexible, fibre-optic endoscopies were available. A modified version, easier to follow, was first described in 1987.

Modified Baron score:

Normal	Mild	Moderate	Severe
Normal mucosa	Erythema	Marked erythema	Spontaneous bleeding
Inactive disease	Decreased vascular pattern	Loss of vascular pattern	Ulceration
		Mucosal friability	

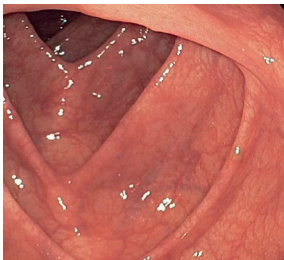


Fig 43. Ulcerative colitis, Baron score, normal mucosa

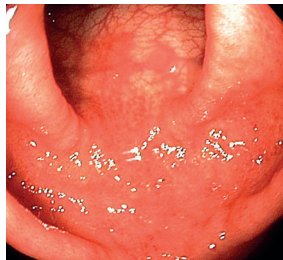

Fig 44. Ulcerative colitis, Baron score, mild disease

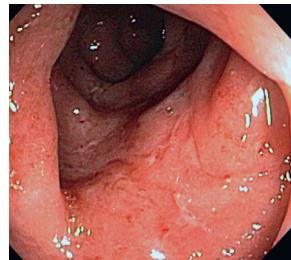


Fig 45. Ulcerative colitis, Baron score, moderate disease

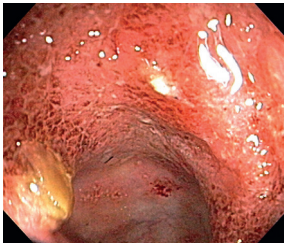


Fig 46. Ulcerative colitis, Baron score, severe disease

References: Baron JH, Connell AM, Lennard-Jones J. Variation between observers in describing mucosal appearances in proctocolitis. *Br Med J.* 1964;1:89–92. Schroeder KW, Tremaine WJ, Ilstrup DM. Coated oral 5-aminosalicylic acid therapy for mildly to moderately active ulcerative colitis. *N Engl J Med* 1987;317:1625–19.

Photos supplied by:

MD Anders Neuman, Viborg Regional hospital, Denmark fig. 43

TT Nyhetsbyrå AB: fig. 44

David Musher/Science Source: fig 45,46