

Endoscopic indices

Mayo Ulcerative Colitis Endoscopic Score

Mayo endoscopic score is often used in clinical trials. It is a part of the original Mayo score but is often – and easier – used alone.

Score	0	1	2	3
Mucosal appearance	Normal	Mild disease: erythema, decreased vascular pattern, mild friability	Moderate disease: marked erythema, absent vascular pattern, friability, erosions	Severe disease: spontaneous bleeding, ulceration

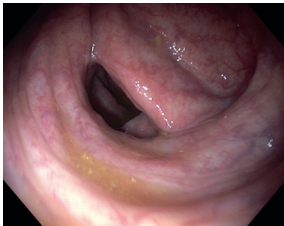


Fig 35. Ulcerative colitis, Mayo endoscopic score 0 (normal)

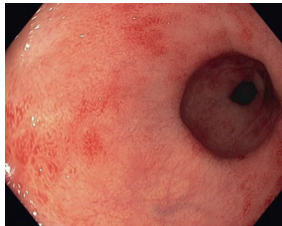


Fig 36. Ulcerative colitis, Mayo endoscopic score 1 (mild)

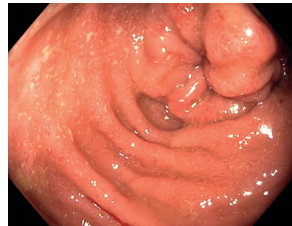

Fig 37. Ulcerative colitis, Mayo endoscopic score 2 (moderate)

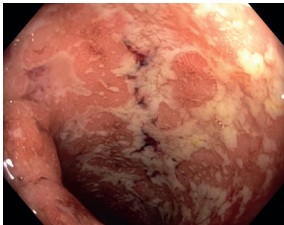


Fig 38. Ulcerative colitis, Mayo endoscopic score 3 (severe)

Reference: Schroeder KW, Tremaine WJ, Ilstrup DM. Coated oral 5-aminosalicylic acid therapy for mildly to moderately active ulcerative colitis. N Eng J Med. 1987;317:1625–1629.

Photos supplied by:

DR Trond Espen Detlie, Akerhus University hospital, Norway: fig. 35, 37, 38

MD Anders Neumann, Viborg Regional hospital, Denmark: fig 36